

### Liver Tumors in Children

JASON B. LITTEN,<sup>a</sup> GAIL E. TOMLINSON<sup>a-c</sup>

Departments of <sup>a</sup>Pediatrics and <sup>b</sup>Internal Medicine, University of Texas Southwestern Medical Center, Dallas, Texas; <sup>c</sup>Greehey Children's Cancer Research Institute, The University of Texas Health Science Center at San Antonio, San Antonio, Texas

**Key Words.** Pediatric cancer • Liver tumor • Hepatoblastoma

**Disclosure:** The content of this article has been reviewed by independent peer reviewers to ensure that it is balanced, objective, and free from commercial bias. No financial relationships relevant to the content of this article have been disclosed by the authors, planners, independent peer reviewers, or staff managers.

#### LEARNING OBJECTIVES

After completing this course, the reader should be able to:

1. Describe the current epidemiologic trends in hepatoblastoma.
2. Identify the genetic syndromes that are seen in a subset of liver tumors.
3. Assess the need for complete tumor resection in the treatment of liver tumors in children as well as the increasingly important option of liver transplantation for those patients with unresectable tumors.
4. Discuss the impact of the hepatitis vaccine in reducing the incidence of hepatocellular carcinoma.
5. Explain the prognostic impact of different histologic subtypes of hepatoblastoma.
6. Promote the need for future clinical trials in testing new agents for hepatocellular carcinoma in children.
7. Employ the different staging systems used in liver tumors, including the traditional North American postsurgical staging system and the European presurgical staging system using imaging.

CME

This article is available for continuing medical education credit at [CME.TheOncologist.com](http://CME.TheOncologist.com).

#### ABSTRACT

**Malignant liver tumors account for slightly >1% of all pediatric malignancies, with roughly 150 new cases of liver tumors diagnosed in the U.S. annually. The embryonal tumor, hepatoblastoma, accounts for two thirds of malignant liver tumors in children. Other liver malignancies in children include hepatocellular carcinoma, sarcomas, germ cell tumors, and rhabdoid tumors. Benign tumors of the liver in children include vascular tu-**

**mors, hamartomas, and adenomas. There is an apparent increase in the incidence of hepatoblastoma with perinatal exposures and decreased premature infant mortality as postulated causes for this increased risk. The known causes and associations of liver tumors in children as well as the approaches to diagnosis and treatment of children are discussed in this review article. *The Oncologist* 2008;13:812–820**

Correspondence: Gail E. Tomlinson, M.D., Ph.D., University of Texas Health Science Center at San Antonio, 7703 Floyd Curl Drive, San Antonio, Texas 78229, USA. Telephone: 210-562-9001; Fax: 210-562-9014; e-mail: [tomlinsong@uthscsa.edu](mailto:tomlinsong@uthscsa.edu) Received January 14, 2008; accepted for publication April 5, 2008; first published online in *THE ONCOLOGIST Express* on July 21, 2008. ©AlphaMed Press 1083-7159/2008/\$30.00/0 doi: 10.1634/theoncologist.2008-0011

## INTRODUCTION

Malignant liver tumors account for slightly >1% of all pediatric malignancies. Approximately 100–150 new cases of liver tumors are diagnosed in the U.S. annually [1]. Two thirds of liver tumors in children are malignant [2]. Unlike liver tumors in adults, in which the predominant histology is hepatocellular carcinoma, hepatoblastoma accounts for two thirds of liver tumors in children [1, 2]. Other liver malignancies in children include sarcomas, germ cell tumors, and rhabdoid tumors, as well as the more familiar hepatocellular carcinoma. Benign tumors of the liver in children include vascular tumors, hamartomas, adenomas, and focal nodular hyperplasia. The histology and anatomy of a pediatric liver tumor guides the treatment and prognosis.

## CHANGES IN INCIDENCE OF PEDIATRIC HEPATIC TUMORS

There are several suggestions that the incidence of malignant liver tumors is increasing in the U.S. Surveillance, Epidemiology, and End Results data from 1972–1992 showed a 5% annual increase [1]. Other data showed that liver cancer represented 2% of all malignancies in infants in the early 1980s with the incidence doubling to 4% 10 years later [3]. Although the numbers forming the basis of this increasing rate are small, it has been suggested that our improvements in technology, care, and outcomes for premature infants have been driving forces in this increase in incidence. Investigations initially reported by a Japanese group [4], and later confirmed by U.S. investigators [5, 6], revealed that hepatoblastoma is more commonly diagnosed in children with a history of prematurity than in full-term infants. Interestingly, those tumors that arise in ex-premature infants do not present at a younger age than those of term infants.

## HEPATOBLASTOMA: THE MOST COMMON PEDIATRIC LIVER TUMOR

Hepatoblastoma is the most common malignant tumor of the liver in children. For poorly understood reasons, hepatoblastoma occurs in males significantly more frequently than it does in females [2]. Hepatoblastomas are composed of cells resembling the developing fetal and embryonic liver, hence the classification as an embryonal tumor. Indeed, the cells comprising hepatoblastoma mark similarly to hepatic stem cells, defined as pluripotent hepatoblasts capable of differentiating into hepatocytes or cholangiocytes [7, 8]. Hepatoblastoma is diagnosed in very young children with a peak in the newborn period reflecting those tumors that developed prenatally, and an overall median age at di-

agnosis of 18 months, as shown in Figure 1. Only 5% of new hepatoblastoma cases are diagnosed in children >4 years of age.

Most commonly, these tumors present in the right lobe of the liver [9]. Histologically, these tumors can be divided into epithelial or mixed epithelial/mesenchymal tissue. The majority of hepatoblastomas are epithelial and consist of a mixture of embryonal and fetal cell types (Fig. 2). Approximately 5% of hepatoblastomas are of the small cell undifferentiated subtype. This subtype is associated with a worse prognosis [10].

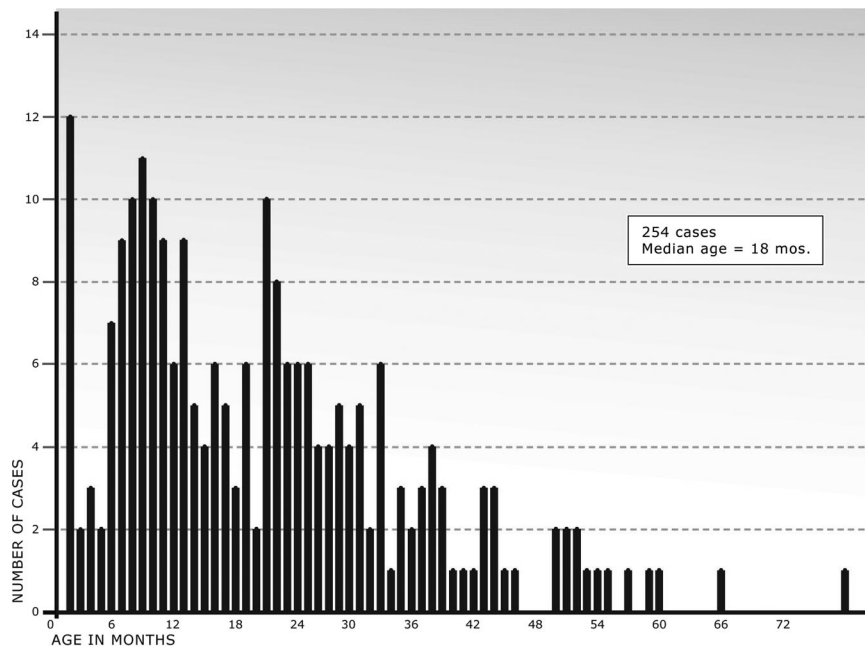
## HEPATOCELLULAR CARCINOMA

Hepatocellular carcinoma, the second most common malignancy of the liver in children, is markedly distinct from hepatoblastoma. Most cases of hepatocellular carcinoma are diagnosed after 10 years of age. Hepatocellular carcinoma is the most common hepatic malignancy of adolescents. Often, hepatocellular carcinoma is associated with known hepatic viral infection or cirrhosis, and while it can take decades for malignancy to develop, occasionally cases are seen in very young children.

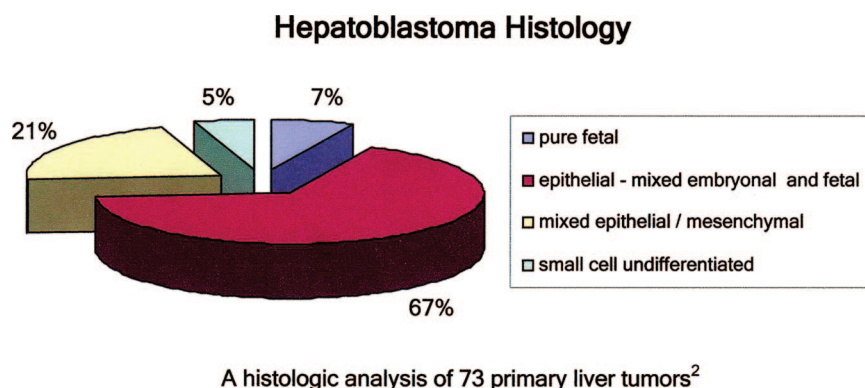
Previous reports from Southeast Asia cite an annual incidence of pediatric hepatic tumors that is roughly four times higher than western reports in children <15 years of age [11]. This finding is largely based on the high hepatitis carrier rate, with a Taiwanese report stating that 80% of primary liver tumors in children were hepatocellular carcinoma. With the introduction of hepatitis B vaccine in Southeast Asia, however, there has been a marked reduction in the incidence of hepatocellular carcinoma, although the impact of the hepatitis B vaccine has mainly reduced the incidence of liver tumors in males [12]. Occasionally, malignant tumors in children are seen with features of both hepatocellular carcinoma and hepatoblastoma. These tumors are more common in children with a diagnosis at later ages than that typical of hepatoblastoma.

## SARCOMAS AND OTHER MALIGNANT TUMORS OF THE LIVER

The third most common hepatic malignancy, after hepatoblastoma and hepatocellular carcinoma, is undifferentiated embryonal sarcoma [13, 14]. These tumors occur in children 5–10 years of age and are mesenchymal in appearance. While the vast majority of vascular tumors of the liver in childhood are benign hemangioendotheliomas, angiosarcoma of the liver is a particularly aggressive malignant subtype with a poor prognosis [15, 16]. Embryonal rhabdomyosarcomas arise from biliary ducts and usually arise in children <5 years of age [17]. These children typically present with jaundice secondary to biliary obstruction and



**Figure 1.** Age distribution of hepatoblastoma derived from 254 sequential cases representing all stages and histologies of hepatoblastoma. An initial peak is seen at birth reflecting tumors developing during gestation. The median age of all children with hepatoblastoma is 18 months and the oldest age is 78 months. Ninety-nine percent of cases were observed to occur by age 5 years of age (unpublished data).



**Figure 2.** Distribution of histologic subtypes of hepatoblastoma. The majority are epithelial and consist of embryonal and fetal cell types. Pure fetal histology accounts for approximately 7% of hepatoblastomas and is associated with a favorable prognosis. Small cell undifferentiated hepatoblastoma accounts for 5% of hepatoblastoma cases and is associated with a poor prognosis.

have been treated in a similar fashion to those with rhabdomyosarcoma in other sites. Primary extragonadal germ cell tumors within the hepatic parenchyma have been reported [18], but the hepatic parenchyma is more commonly seen as a site of germ cell tumor metastases [19].

### BENIGN TUMORS OF THE LIVER

Benign tumors of the liver account for almost 30% of all liver tumors in children. Between 40 and 50 cases are diagnosed in the U.S. per year, with hemangioma being the most common benign tumor. These vascular tumors are usually diagnosed in the first 6 months of life and show a preponderance in whites and females [20]. Hemangiomas are characterized

by a period of rapid growth followed by involution. Although benign in their pathology and potential to metastasize, these tumors are still associated with significant morbidity and mortality, leading to the classic triad of hepatomegaly, congestive heart failure, and anemia [21]. These children may also present with consumptive coagulopathy (Kasaback-Merritt syndrome) and bleeding [22]. Arteriovascular malformations are rarer than hemangioma but may have a similar presentation [23, 24]. Mesenchymal hamartoma is a benign entity that can sometimes be seen on a prenatal ultrasound, but usually presents as an asymptomatic abdominal mass after a period of rapid growth and can cause compression of adjacent tissue but is curable by resection [25].

**Table 1.** Constitutional genetic syndromes associated with pediatric liver tumors

Disease	Tumor type	Chromosome locus	Gene
Familial adenomatous polyposis	Hepatoblastoma, adenoma, hepatocellular carcinoma, biliary adenoma	5q21.22	<i>APC</i>
Beckwith-Wiedemann syndrome	Hepatoblastoma, hemangioendothelioma	11p15.5	<i>p57KIP2</i> , others
Li-Fraumeni syndrome	Hepatoblastoma, undifferentiated sarcoma	17p13	<i>TP53</i> , others
Trisomy 18	Hepatoblastoma	18	?
Glycogen storage disease type I	Hepatocellular adenoma, carcinoma, hepatoblastoma	17	Glucose-6-phosphatase
Hereditary tyrosinemia	Hepatocellular carcinoma	15q23-25	Fumarylaceto-acetate hydrolase
Alagille syndrome	Hepatocellular carcinoma	20p12	<i>JAG1</i>
Other familial cholestatic syndromes	Hepatocellular carcinoma	18q21-22, 2q24	<i>FIC1</i> , <i>BSEP</i>
Neurofibromatosis	Hepatocellular carcinoma, malignant schwannoma, angiosarcoma	17q11.2	<i>NF-1</i>
Ataxia-telangiectasia	Hepatocellular carcinoma	11q22-23	<i>ATM</i>
Fanconi anemia	Hepatocellular carcinoma, fibrolamellar cancer, adenoma	1q42, 3p, 20q, 13.2-13.3, Others	<i>FAA</i> , <i>FAC</i> , others (20%)
Tuberous sclerosis	Angiomyolipoma	9q34, 16p13	<i>TSC1</i> , <i>TSC2</i>

**Table 2.** Liver tumor staging systems

	European staging, SIOPEL/PRETEXT Presurgical staging	North American staging Postsurgical staging
Stage 1	Tumor involves only one quadrant; three adjoining liver quadrants are free of tumor	No metastases; tumor completely resected
Stage 2	Tumor involves two adjoining quadrants; two adjoining quadrants are free of tumor	No metastases; tumor grossly resected with microscopic residual disease (i.e., positive margins, tumor rupture, or tumor spill at the time of surgery)
Stage 3	Tumor involves three adjoining quadrants or two nonadjoining quadrants; one quadrant or two nonadjoining quadrants are free of tumor	No distant metastases; tumor unresectable or resected with gross residual tumor, or positive nodes
Stage 4	Tumor involves all four quadrants; there is no quadrant free of tumor	Distant metastases regardless of the extent of liver involvement

Abbreviations: PRETEXT, PRETreatment EXTent of disease scoring system; SIOPEL, Childhood Liver Tumor Strategy Group of the Société Internationale d'Oncologie Pédiatrique. Adapted from National Cancer Institute Website <http://www.cancer.gov/cancertopics/pdq/treatment/childliver>. Accessed on February 27, 2008.

## GENETICS AND PEDIATRIC LIVER TUMORS

Hepatoblastoma is associated with several genetic syndromes and familial cancer predisposition conditions, such as familial adenomatous polyposis [26] and Beckwith-Wiedemann syndrome [27] in addition to several other rare syndromes, as listed in Table 1. Similar to other embryonal tumors, altered imprinting at the 11–15 locus has been observed in hepatoblastoma [28]. Other compelling evidence suggests that acquired aberrations in the  $\beta$ -catenin/Wnt pathways are important in the pathogenesis of hepatoblastoma [29, 30]. Acquired chromosomal changes in tumors include numerical chromosomal

changes, most commonly trisomies of chromosomes 2, 8, and 20 [31]. Rearrangements involving the pericentric region of chromosome 1 also appear to be important in hepatoblastoma, with roughly 18% of hepatoblastomas displaying an imbalanced translocation involving this region [32, 33]. Finally, epigenetic changes in methylation patterns of DNA may be altered in hepatoblastoma [34].

## ENVIRONMENTAL FACTORS

There is limited but compelling evidence that parental exposures are associated with a higher incidence of liver tu-

mors and, more specifically, hepatoblastoma. Children from parents who have been exposed to metals used in soldering and welding, petroleum, or paints are at a higher risk for hepatoblastoma [35]. Recent reports have also implicated parental smoking as a risk factor for hepatoblastoma [36, 37].

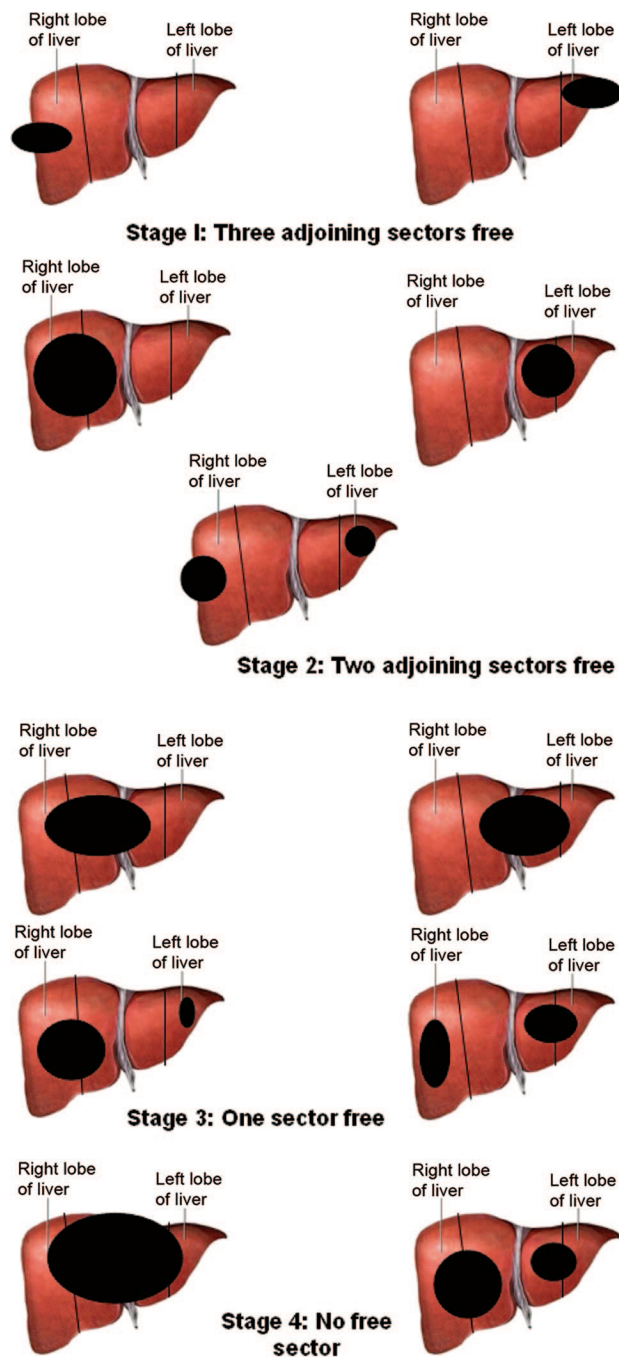
### PRESENTATION AND ASSESSMENT OF A LIVER MASS

The child with a liver tumor usually presents with a painless palpable abdominal mass. Occasionally, precocious puberty can be observed from the  $\beta$ -human chorionic gonadotropin  $\beta$ -HCG–eluting tumor. Likewise, thrombocytosis is frequently observed secondary to increased levels of thrombopoietin secreted by the tumor [38]. Sometimes children will complain of abdominal pain or constipation, but these children generally have normal liver function and are not jaundiced. An important exception to this general rule is in the context of viral hepatitis and hepatocellular carcinoma. These children may be jaundiced and have hepatic cirrhosis. A subset of hepatocellular carcinoma, the fibrolamellar variant, is an exception in that the adjacent liver, like that in hepatoblastoma, is normal appearing. Generally, children with liver masses display normal growth and development unless they show the phenotypes associated with Beckwith-Wiedemann syndrome or the other genetic cancer predisposition syndromes associated with liver tumors listed in Table 1. These syndromes, however, collectively are seen in <20% of liver tumors.

### EVALUATION

All children with a palpable abdominal mass usually undergo either an initial plain film x-ray or an ultrasound; however, definitive characterization of the mass requires a computed tomography (CT) or magnetic resonance imaging (MRI) scan. Calcifications can be seen in a minority of liver tumors. A chest CT is an important aspect of the workup because the lung parenchyma is the most common distant site for metastasis. A CBC typically displays mild normocytic and normochromic anemia with thrombocytosis. Any child with a suspected liver tumor should have  $\alpha$ -fetoprotein (AFP) and  $\beta$ -HCG serum assays. AFP is markedly elevated in >90% of hepatoblastoma cases and in many cases of hepatocellular carcinoma, and it returns to normal with effective therapy [39]. Likewise,  $\beta$ -HCG is a hormone commonly produced by liver tumors and, in excess, can result in precocious puberty. Caution should be taken in normal term infants who can have AFP levels in excess of 100,000 ng/ml; however, with a half-life of approximately 1 week, the AFP level normalizes to <10 ng/ml over the first few months of life.

Because of the association between familial adenomatous



**Figure 3.** The PRETreatment EXTent of disease scoring system (PRETEXT) involves classification of liver tumors by dividing the liver on imaging into four sectors and determining how many sectors are involved by tumors. Extension of the tumor is also included in the staging as follows: V indicates extension into the vena cava and/or all three hepatic veins; P indicates extension into the main branch and/or both the left and right branches of the portal vein; E indicates extrahepatic disease, and unlike P and V is rare and must be biopsy proven; M indicates the presence of distant metastases [54, 55].

polyposis and hepatoblastoma, obtaining a thorough family history is an important aspect of the management of a child

**Table 3.** Summary of recent cooperative group studies in Europe and North America

Study	Presurgical chemotherapy	Chemotherapy	n of patients	Outcomes
POG-8697 [56]	No	C5V	73	3-yr EFS: stage I(UH)/II, 91%; stage III, 67%; stage IV, 12.5%
COG-9645 [57]	Yes	C5V versus intensified platinum <sup>a</sup>	33	5-yr EFS: stage III, 73%; stage IV, 27%
INT-0098 [46]	Selected patients	C5V versus cisplatin and doxorubicin	182	5-yr EFS: stage I(UH)/II, >90%; stage III/IV, >50%
HB-89 [58]	Yes	Ifosphamide, cisplatin, doxorubicin	72	3-yr EFS: stage I, 100%; stage II, 50%; stage III, 74%; stage IV, 29%
HB-94 [59]	Selected patients	Ifosphamide, cisplatin, doxorubicin	69	3-yr EFS/OS: stage I, 96%; stage II, 100%; stage III, 76%; stage IV, 36%
SIOPEL-1 [42]	Yes	Cisplatin and doxorubicin	160	3-yr OS, 75%
SIOPEL-2 [60]	Yes	Cisplatin/carboplatin and doxorubicin	150	3-yr OS <sup>b</sup> : SR, 90%; HR, 78%

<sup>a</sup>Only stage II and IV patients enrolled.

<sup>b</sup>SR defined as hepatoblastoma confined to the liver and involving no more than three hepatic sectors; HR defined as hepatoblastoma extending into all four sectors and/or lung metastases and/or extrahepatic involvement.

Abbreviations: C5V, cisplatin, vincristine, and fluorouracil; COG, Children's Oncology Group; EFS, event-free survival; HB, hepatoblastoma; HR, high risk; OS, overall survival; POG, pediatric Oncology Group; SIOPEL, Childhood Liver Tumor Strategy Group of the Société Internationale d'Oncologie Pédiatrique; SR, standard risk; UH, unfavorable histology.

with a liver tumor and his family, with particular attention to any family history of colon cancer or colonic polyps.

### STAGING

Historically, North Americans have staged liver tumors similar to other solid tumors, with surgical resectability and the presence of metastases as the primary criteria (Table 2). The European staging system considers only the pretreatment extent of disease (i.e., the PRETreatment EXTent of disease scoring system [PRETEXT]), and was developed by the Childhood Liver Tumor Strategy Group of the Société Internationale d'Oncologie Pédiatrique, SIOPEL [40]. As shown in Figure 3, the PRETEXT staging system divides the liver into four sectors, and the number of segments involved by tumor indicates stage. A lettering system further indicates extrahepatic involvement. This staging system has been useful in determining treatment plans and offers good prognostic value for overall and disease-free survival outcomes [41, 42].

### TREATMENT

Through the work of cooperative groups around the world, treatment of hepatoblastoma has improved markedly over the past several decades. During this time, therapy has evolved from surgery alone with a poor prognosis to multimodal therapy, with some patients achieving a >90% long-term survival probability [43]. This improvement is

seen most clearly for those children with initially unresectable hepatoblastoma. A comparison of European and North American trials is shown in Table 3.

Hepatocellular carcinoma is so infrequent in children that these patients have often been treated according to hepatoblastoma regimens, albeit with far less success. Recently, sorafenib, a multikinase inhibitor, was approved by the U.S. Food and Drug Administration for the first-line treatment of hepatocellular carcinoma after a study in adults demonstrated efficacy in advanced-stage hepatocellular carcinoma [44], but no data exist on its use in children. The approach to treatment of less common malignant tumors of the liver parallels the approach to the tumors with similar histology, that is, a primary hepatic sarcoma is generally treated like sarcomas in other anatomical sites.

Surgical resection is the most important therapeutic modality for the treatment of hepatic tumors. The surgeon must carefully evaluate the tumor and surrounding anatomy with MRI, CT, and/or a hepatic angiogram to determine if the tumor is resectable. At the time of resection, surrounding lymph nodes are sampled and submitted for pathologic review. If pulmonary nodules are present, an attempt at resection should be made, because this is thought to improve survival. Primary resection alone can be curative in the case of benign liver tumors and stage I hepatoblastoma of pure fetal histology.

Because of the large tumor bulk and involvement of multiple liver sectors, a primary resection is not possible in >60% of cases [45]. Therefore, systemic neoadjuvant chemotherapy is necessary and often shows impressive results. In those patients with initially unresectable tumors, an early decline in serum AFP with chemotherapy suggests a favorable outcome [41].

Recent cooperative group protocols for hepatoblastoma and hepatocellular carcinoma have involved vincristine, cisplatin, and fluorouracil in four cycles [46]. Doxorubicin has also been noted as an active agent and continues to be used throughout Europe [47]. Toxicity in previous North American trials has limited its use [46]; however, there are ongoing discussions regarding the reintroduction of doxorubicin in North American clinical trials.

Despite aggressive chemotherapy, 25%–30% of initially unresectable tumors remain resistant to treatment. Radiation is not an important therapeutic consideration in the treatment of hepatic tumors because of the normal liver parenchyma's limited maximum-tolerated dose [48].

The strategy of a complete hepatectomy and subsequent orthotopic liver transplantation has been used with success in treating unresectable liver tumors. Currently, liver malignancies account for roughly 1 in 50 liver transplantations in children. A series of 31 patients, published in 2000,

showed that the post-transplant 5-year survival rate for hepatoblastoma was 86%, and this rate was 83% for hepatocellular carcinoma. As immunosuppressive regimens have improved, a steady improvement in the success of hepatic transplant patients has been seen [49, 50]. In addition, living donor transplantation has become an option [49, 50]. Ongoing questions regarding the management of post-transplant patients surround the use of adjuvant chemotherapy and the prioritization of transplant candidates [51].

## FUTURE DIRECTIONS

While amenability to surgical resection and surgical technique advances remain the most important aspects of pediatric liver tumor therapy, new chemotherapeutic agents with less toxicity are needed. Imaging modalities such as positron emission tomography CT [52] and anti-AFP imaging [53] hold promise for better surgical outcomes and greater sensitivity for residual or relapsed disease. As more is understood regarding the molecular pathways in hepatoblastoma, it is hoped that additional targeted therapies will be developed.

## AUTHOR CONTRIBUTIONS

**Conception/design:** Jason B. Litten, Gail E. Tomlinson

**Administrative support:** Jason B. Litten, Gail E. Tomlinson

**Collection/assembly of data:** Jason B. Litten, Gail E. Tomlinson

**Data analysis and interpretation:** Gail E. Tomlinson

**Manuscript writing:** Jason B. Litten, Gail E. Tomlinson

**Final approval of manuscript:** Jason B. Litten, Gail E. Tomlinson

## REFERENCES

- Multerys M, Goodman MT, Smith MA et al. Hepatic Tumors. In Ries LAG, Smith MA, Gurney JG et al. (eds). *Cancer Incidence, Survival among Children, Adolescents: United States SEER Program 1975–1995*. SEER Program, NIH Pub. No 99–4649. Bethesda, MD: National Cancer Institute, 1999:91–97.
- Weinberg AG, Finegold MJ. Primary hepatic tumors of childhood. *Hum Pathology* 1983;14:512–537.
- Kenney LB, Miller BA, Ries LA et al. Incidence of cancer in infants in the U.S.: 1980–1990. *Cancer* 1998;82:1396–1400.
- Ikeda H, Matsuyama S, Tanimura M. Association between hepatoblastoma and very low birth weight: A trend or chance? *J Pediatr* 1997;130:557–560.
- Reynolds P, Urayama KY, Von Behren J et al. Birth characteristics and hepatoblastoma risk in young children. *Cancer* 2004;100:1070–1076.
- Spector LG, Feusner JH, Ross JA. Hepatoblastoma and low birth weight. *Pediatr Blood Cancer* 2004;43:706.
- Ruck P, Xiao JC, Pietsch T et al. Hepatic stem-like cells in hepatoblastoma: Expression of cytokeratin 7, albumin and oval cell associated antigens detected by OV-1 and OV-6. *Histopathology* 1997;31:324–329.
- Ruck P, Xiao JC. Stem-like cells in hepatoblastoma. *Med Pediatr Oncol* 2002;39:504–507.
- Exelby PR, Filler RM, Grosfeld JL. Liver tumors in children in the particular reference to hepatoblastoma and hepatocellular carcinoma: American Academy of Pediatrics Surgical Section Survey–1974. *J Pediatr Surg* 1975;10:329–337.
- Haas JE, Feusner JH, Finegold MJ. Small cell undifferentiated histology in hepatoblastoma may be unfavorable. *Cancer* 2001;92:3130–3134.
- Chen JC, Chang ML, Lin JN et al. Comparison of childhood hepatic malignancies in a hepatitis B hyper-endemic area. *World J Gastroenterol* 2005;11:5289–5294.
- Chang MH, Chen CJ, Lai MS et al. Universal hepatitis B vaccination in Taiwan and the incidence of hepatocellular carcinoma in children. Taiwan Childhood Hepatoma Study Group. *N Engl J Med* 1997;336:1855–1859.
- Bisogno G, Pilz T, Perilongo G et al. Undifferentiated sarcoma of the liver in childhood: A curable disease. *Cancer* 2002;94:252–257.
- Lack EE, Schloo BL, Azumi N et al. Undifferentiated (embryonal) sarcoma of the liver. Clinical and pathological study of 16 cases with emphasis on immunohistochemical features. *Am J Surg Pathol* 1991;15:1–16.
- Awan S, Davenport M, Portmann B et al. Angiosarcoma of the liver in children. *J Pediatr Surg* 1996;31:1729–1732.
- Dimashkieh HH, Mo JQ, Wyatt-Ashmead J et al. Pediatric hepatic angiosarcoma: Case report and review of the literature. *Pediatr Dev Pathol* 2004;7:527–532.
- Nicol K, Savell V, Moore J et al.; Children's Oncology Group, Soft Tissue Sarcoma Committee. Distinguishing undifferentiated embryonal sarcoma of the liver from biliary tract rhabdomyosarcoma: A Children's Oncology Group study. *Pediatr Dev Pathol* 2007;10:89–97.
- Verma M, Agarwal S, Mohta A. Primary mixed germ cell tumour of the liver—a case report. *Indian J Pathol Microbiol* 2003;46:658–659.
- Brodeur GM, Howarth CB, Pratt CB et al. Malignant germ cell tumors in 57 children and adolescents. *Cancer* 1981;48:1890–1898.

- 20 Reddy KR, Kligerman S, Levi J et al. Benign and solid tumors of the liver: Relationship to sex, age, size of tumors, and outcome. *Am Surg* 2001;67:173–178.
- 21 Selby DM, Stocker JT, Waclawiw MA et al. Infantile hemangioendothelioma of the liver. *Hepatology* 1994;20:39–45.
- 22 Skopec LL, Lakutua DJ. Non-immune fetal hydrops with hepatic hemangioendothelioma and Kasabach-Merritt syndrome: A case report. *Pediatr Pathol* 1989;9:87–93.
- 23 Prokurat A, Kluge P, Chrupek M et al. Hemangioma of the liver in children: Proliferating vascular tumor or congenital vascular malformation. *Med Pediatr Oncol* 2002;39:524–529.
- 24 Burrows PE, Dubois J, Kassarian A. Pediatric hepatic vascular anomalies. *Pediatr Radiol* 2001;31:533–545.
- 25 Siddiqui MA, McKenna BJ. Hepatic mesenchymal hamartoma: A short review. *Arch Pathol Lab Med* 2006;130:1567–1569.
- 26 Kingston JE, Herbert A, Draper GJ et al. Association between hepatoblastoma and polyposis coli. *Arch Dis Child* 1983;58:959–962.
- 27 DeBaun MR, Tucker MA. Risk of cancer during the first four years of life in children from the Beckwith-Wiedemann Syndrome Registry. *J Pediatr* 1998;132:398–400.
- 28 Rainier S, Dobry CJ, Feinberg AP. Loss of imprinting in hepatoblastoma. *Cancer Res* 1995;55:1836–1838.
- 29 Park WS, Oh RR, Park JY et al. Nuclear localization of beta-catenin is an important prognostic factor in hepatoblastoma. *J Pathol* 2001;193:483–490.
- 30 Monga SP, Mars WM, Padiaditakis P et al. Hepatocyte growth factor induces Wnt-independent nuclear translocation of beta-catenin after Met-beta-catenin dissociation in hepatocytes. *Cancer Res* 2002;62:2064–2071.
- 31 Tomlinson GE, Douglass EC, Pollock BH et al. Cytogenetic evaluation of a large series of hepatoblastomas: Numerical abnormalities with recurring aberrations involving 1q12–q21. *Genes Chromosomes Cancer* 2005;44:177–184.
- 32 Schneider NR, Cooley LD, Finegold MJ et al. The first recurring chromosome translocation in hepatoblastoma: der(4)t(1;4)(q12;q34). *Genes Chromosomes Cancer* 1997;19:291–294.
- 33 Parada LA, Limon J, Iliszko M et al. Cytogenetics of hepatoblastoma: Further characterization of 1q rearrangements by fluorescence in situ hybridization: An International collaborative study. *Med Pediatr Oncol* 2000;34:165–170.
- 34 Shim YH, Park HJ, Choi MS et al. Hypermethylation of the p16 gene and lack of p16 expression in hepatoblastoma. *Mod Pathol* 2003;16:430–436.
- 35 Buckley JD, Sather H, Ruccione K et al. A case-control study of risk factors for hepatoblastoma. A report from the Children's Cancer Study Group. *Cancer* 1989;64:1169–1176.
- 36 Pang D, McNally R, Birch JM. Parental smoking and childhood cancer: Results from the United Kingdom Childhood Cancer Study. *Br J Cancer* 2003;88:373–381.
- 37 Sorahan T, Lancashire RJ. Parental cigarette smoking and childhood risks of hepatoblastoma: OSCC data. *Br J Cancer* 2004;90:1016–1018.
- 38 Komura E, Matsushima T, Kato T et al. Thrombopoietin in patients with hepatoblastoma. *STEM CELLS* 1998;16:329–333.
- 39 Van Tornout JM, Buckley JD, Quinn JJ et al. Timing and magnitude of decline in alpha-fetoprotein levels in treated children with unresectable or metastatic hepatoblastoma are predictors of outcome: A report from the Children's Cancer Group. *J Clin Oncol* 1997;15:1190–1197.
- 40 Roebuck DJ, Aronson D, Clapuyt P et al. 2005 PRETEXT: A revised staging system for primary malignant liver tumours of childhood developed by the SIOPEL group. *Pediatr Radiol* 2007;37:123–132.
- 41 Brown J, Perilongo G, Shafford E et al. Pretreatment prognostic factors for children with hepatoblastoma—results from the International Society of Pediatric Oncology (SIOP) study SIOPEL 1. *Eur J Cancer* 2000;36:1418–1425.
- 42 Aronson DC, Schnater JM, Staalman CR et al. Predictive value of pretreatment extent of disease system in hepatoblastoma: Results from the International Society of Pediatric Oncology Liver Tumor Study Group SIOPEL-1 study. *J Clin Oncol* 2005;23:1245–1262.
- 43 Tiao GM, Bobey N, Allen S et al. The current management of hepatoblastoma: A combination of chemotherapy, conventional resection, and liver transplantation. *J Pediatr* 2005;146:204–211.
- 44 Zhu AX. Development of sorafenib and other molecularly targeted agents in hepatocellular carcinoma. *Cancer* 2008;112:250–259.
- 45 Czauderna P, Otte JB, Roebuck DJ et al. Surgical treatment of hepatoblastoma in children. *Pediatr Radiol* 2006;36:187–191.
- 46 Ortega JA, Douglass EC, Feusner JH et al. Randomized comparison of cisplatin/vincristine/fluorouracil and continuous infusion doxorubicin for treatment of pediatric hepatoblastoma: A report from the Children's Cancer Group and the Pediatric Oncology Group. *J Clin Oncol* 2000;18:2665–2675.
- 47 Pritchard J, Brown J, Shafford E et al. Cisplatin, doxorubicin, and delayed surgery for childhood hepatoblastoma: A successful approach—results of the first prospective study of the International Society of Pediatric Oncology. *J Clin Oncol* 2000;18:3819–3828.
- 48 Cromheecke M, Konings AW, Szabo BG et al. Liver tissue tolerance for irradiation: Experimental and clinical investigations. *Hepatogastroenterology* 2000;47:1732–1740.
- 49 Otte JB, de Ville de Goyet J, Reding R. Liver transplantation for hepatoblastoma: Indications and contraindications in the modern era. *Pediatr Transplant* 2005;9:557–565.
- 50 Reyes JD, Carr B, Dvorchik I et al. Liver transplantation and chemotherapy for hepatoblastoma and hepatocellular cancer in childhood and adolescence. *J Pediatr* 2000;136:795–804.
- 51 Otte JB, Pritchard J, Aronson DC et al. Liver transplantation for hepatoblastoma: Results from the International Society of Pediatric Oncology (SIOP) study SIOPEL-1 and review of the world experience. *Pediatr Blood Cancer* 2004;42:74–83.
- 52 Figrola MS, McQuiston SA, Wilson F et al. Recurrent hepatoblastoma with localization by PET-CT. *Pediatr Radiol* 2005;35:1254–1258.
- 53 Kairemo KJ, Lindahl H, Meremies J et al. Anti alpha-fetoprotein imaging is useful for staging in hepatoblastoma. *Transplantation* 2002;73:1151–1154.
- 54 Czauderna P, Otte JB, Aronson DC et al. Guidelines for surgical treatment of hepatoblastoma in the modern era—recommendations from the Childhood Liver Tumour Strategy Group of the International Society of Paediatric Oncology (SIOPEL). *Eur J Cancer* 2005;41:1031–1036.
- 55 Abramson LP, Arensman R. Liver Tumors. Available at <http://www.emedicine.com/ped/topic3035.htm>. Accessed December 27, 2007.
- 56 Douglass EC, Reynolds M, Finegold M et al. Cisplatin, vincristine, and fluorouracil therapy for hepatoblastoma: A Pediatric Oncology Group study. *J Clin Oncol* 1993;11:96–99.
- 57 Katzenstein HM, London WB, Douglass EC et al. Treatment of unresectable and metastatic hepatoblastoma: A Pediatric Oncology Group phase II study. *J Clin Oncol* 2002;20:3438–3444.
- 58 Von Schweinitz D, Byrd DJ, Hecker H et al. Efficiency and toxicity of ifosfamide, cisplatin and doxorubicin in the treatment of childhood hepatoblastoma. Study Committee of the Cooperative Paediatric Liver Tumour Study HB89 of the German Society for Paediatric Oncology and Haematology. *Eur J Cancer* 1997;33:1243–1249.
- 59 Fuchs J, Rydzynski J, Von Schweinitz D et al. Pretreatment prognostic fac-



tors and treatment results in children with hepatoblastoma: A report from the German Cooperative Pediatric Liver Tumor Study HB 94. *Cancer* 2002; 95:172–182.

60 Perilongo G, Shafford E, Maibach R et al. Risk-adapted treatment for childhood hepatoblastoma: Final report of the second study of the International Society of Paediatric Oncology—SIOPEL 2. *Eur J Cancer* 2004;40: 411–421.

**Liver Tumors in Children**

Jason B. Litten and Gail E. Tomlinson

*Oncologist* 2008;13;812-820; originally published online Jul 21, 2008;

DOI: 10.1634/theoncologist.2008-0011

**This information is current as of January 25, 2011**

**Updated Information  
& Services**

including high-resolution figures, can be found at:  
<http://www.TheOncologist.com/cgi/content/full/13/7/812>

 **AlphaMed Press**